ANATOMIA OKA CZŁOWIEKA

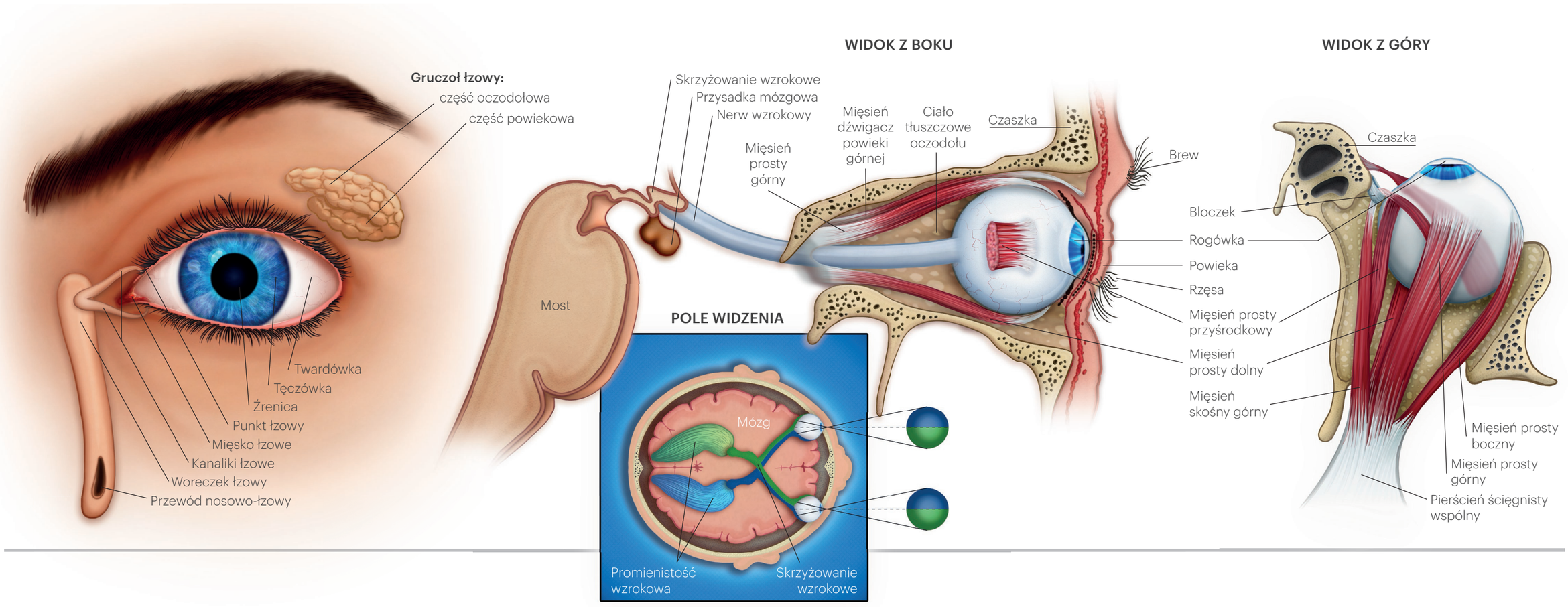

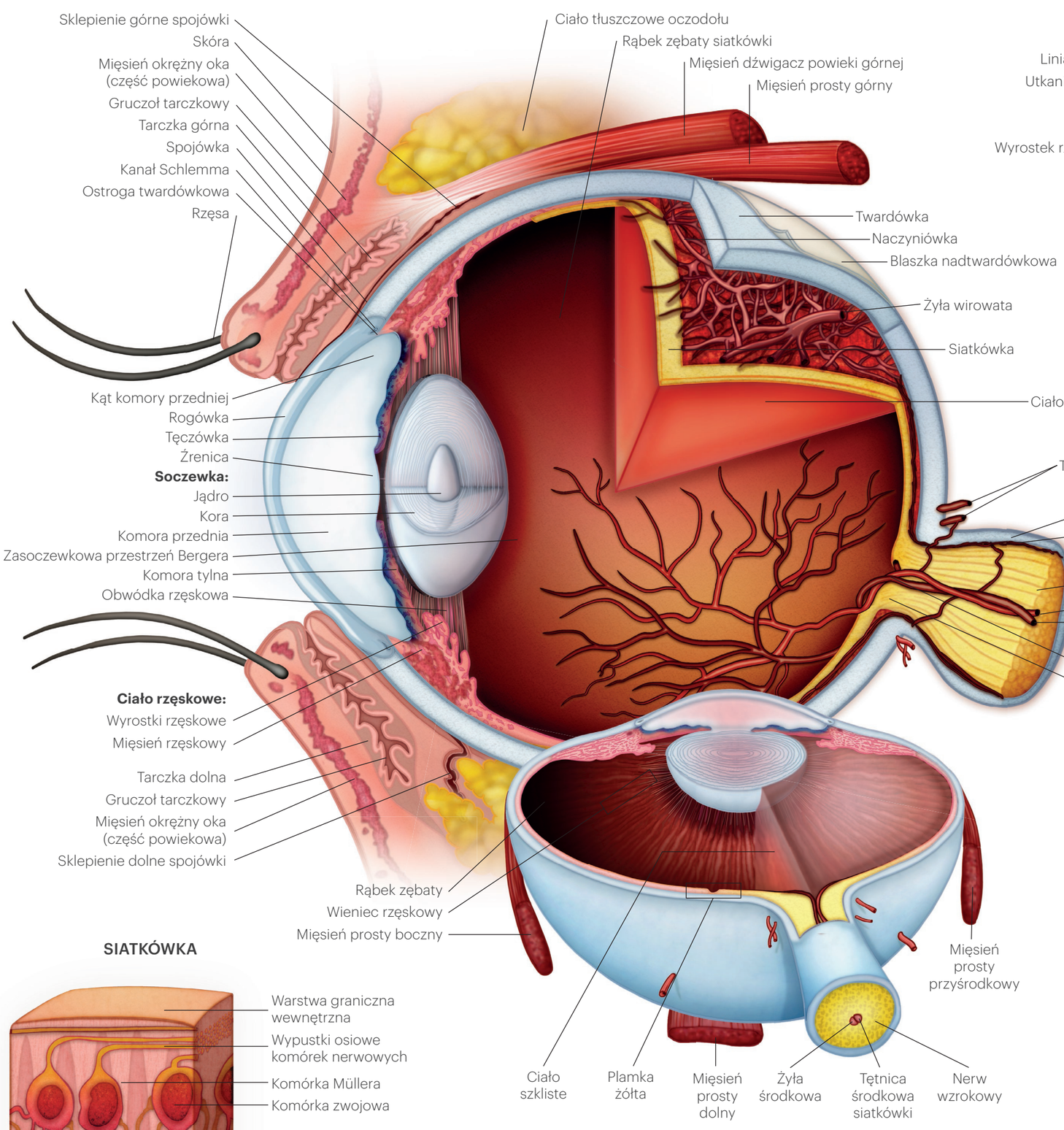

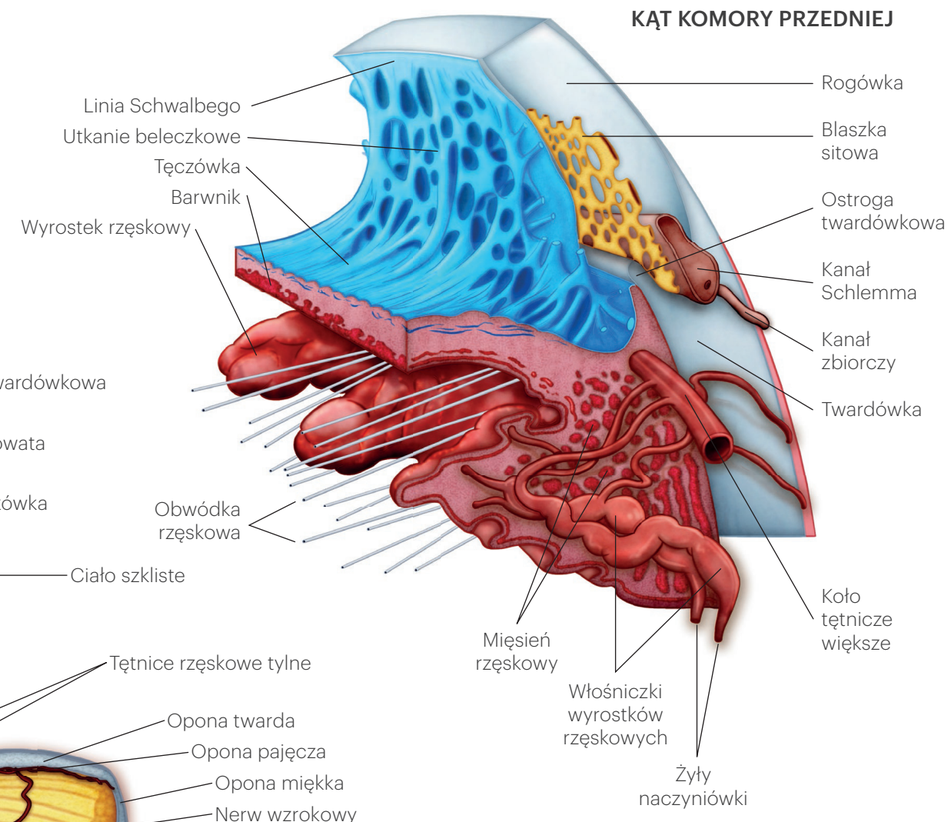

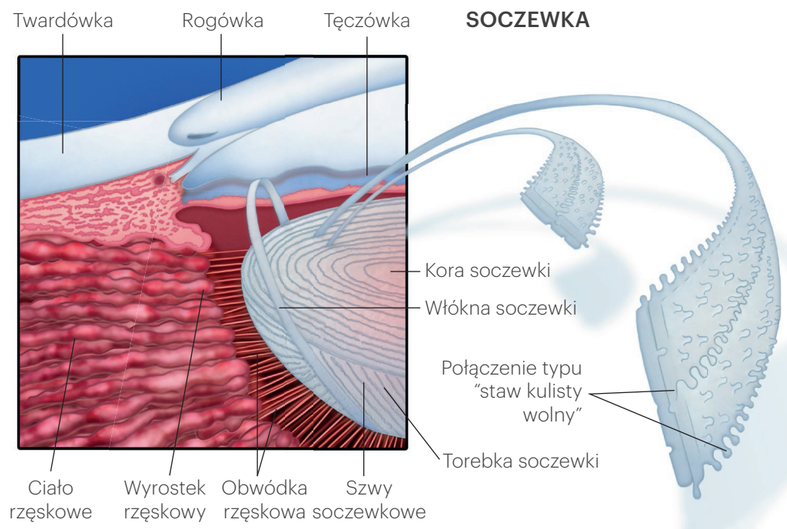

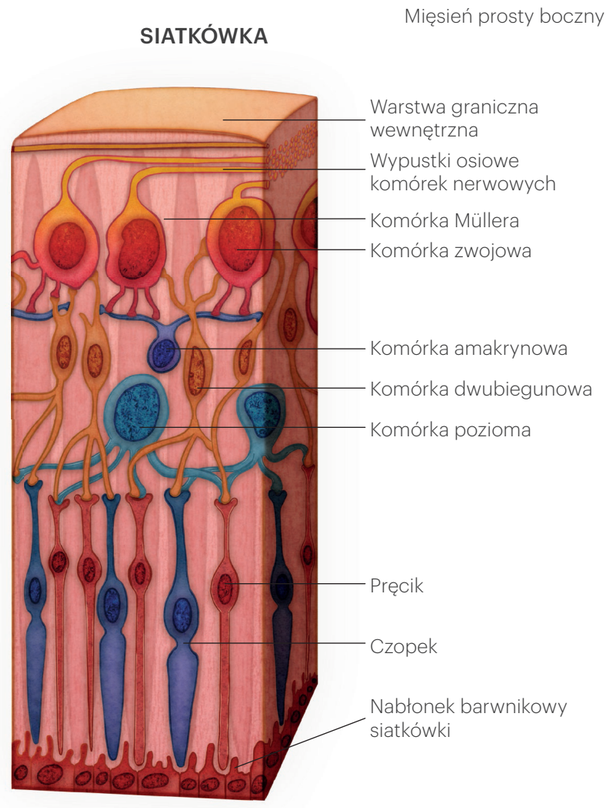

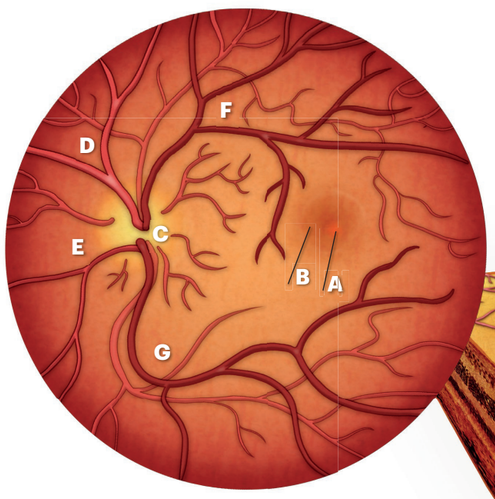

A) Dołek środkowy
B) Plamka żółta
C) Tarcza nerwu wzrokowego
D) Tętniczka nosowa górna siatkówki
E) Tętniczka nosowa dolna siatkówki
F) Tętniczka skroniowa górna siatkówki
G) Tętniczka skroniowa dolna siatkówki

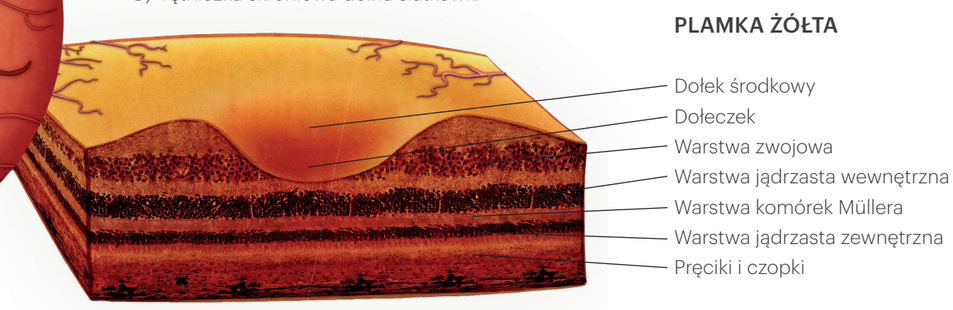

iQ VISION